Case Reports and Reviews

Case Report



Gestational Choriocarcinoma Presenting Four Weeks After Term Delivery: A Case Report

Theresa Okwuegbuna[1] and Adetunji James Ade-Conde[2]

[1]University of Limerick, Ireland
[2]McMaster University, Canada

Correspondence
Theresa Okwuegbuna
University of Limerick, Ireland
Dr. Adetunji James Ade-Conde
McMaster University, Canada

.

- **Received Date**: 21 Oct 2026
- **Accepted Date:** 09 Nov 2026
- **Publication Date**: 11 Nov 2026

Copyright
© 2026 Authors. This is an open- access article distributed under the terms of the Creative Commons Attribution 4.0 International license.

Abstract

Gestational choriocarcinoma is a rare, highly malignant gestational trophoblastic neoplasm that may occur after an uncomplicated term pregnancy. A 38-year-old woman presented with heavy vaginal bleeding and clots four weeks after vacuum-assisted vaginal delivery. Ultrasonography showed a 2.8 × 1.6 × 2.1 cm vascular intrauterine lesion, initially interpreted as retained products of conception. Serum β-human chorionic gonadotropin (β-hCG) was 55,887 IU/L. Uterine evacuation revealed malignant triphasic trophoblastic proliferation comprising cytotrophoblast, syncytiotrophoblast, and intermediate trophoblast. Tumour cells diffusely expressed pancytokeratin, β-hCG, and GATA3; inhibin and SALL4 were focal, p63 was rare, and Ki-67 was high, supporting gestational choriocarcinoma. β-hCG initially declined but subsequently rose, indicating persistent disease. The tumour was classified as FIGO stage I with a modified WHO risk score of 5. The patient underwent a hysterectomy at a regional cancer centre followed by regular β-hCG surveillance. Persistent postpartum bleeding warrants consideration of gestational trophoblastic neoplasia, with serial β-hCG and histopathology essential for diagnosis and monitoring.

Introduction

Gestational trophoblastic disease (GTD) encompasses a heterogeneous group of disorders characterized by abnormal proliferation of placental trophoblastic tissue. GTD includes hydatidiform mole, invasive mole, placental site trophoblastic tumour, epithelioid trophoblastic tumour, and gestational choriocarcinoma [1]. Gestational choriocarcinoma is a highly malignant trophoblastic neoplasm that may occur following a molar pregnancy, spontaneous abortion, ectopic pregnancy, or, less commonly, a term pregnancy [2].

Histologically, gestational choriocarcinoma is characterized by a malignant trophoblastic proliferation composed of cytotrophoblast, syncytiotrophoblast, and intermediate trophoblast, typically accompanied by extensive haemorrhage and necrosis and an absence of chorionic villi. The tumour has a propensity for early haematogenous dissemination, particularly to the lungs, vagina, brain, and liver [2].

The incidence of gestational choriocarcinoma varies according to geographic region, population, and the nature of the antecedent pregnancy.3 Although molar pregnancy is an important risk factor, gestational choriocarcinoma may occur following an otherwise uncomplicated term pregnancy [3].

We report a case of gestational choriocarcinoma in a 38-year-old woman who presented with heavy vaginal bleeding four weeks following a vacuum-assisted vaginal delivery of a term infant. The initial clinical and radiological impression was retained products of conception. This case highlights the importance of considering gestational trophoblastic neoplasia in the differential diagnosis of abnormal or persistent postpartum bleeding and demonstrates the diagnostic value of quantitative and persistent serum β-human chorionic gonadotropin (β-hCG) measurement in this setting.

Case Presentation

A 38-year-old woman with a history of uterine polyps, menorrhagia, dysmenorrhoea, and dyspareunia was initially referred for investigation of infertility. Her medical history was otherwise unremarkable. Her social history was notable for smoking approximately three to five cigarettes daily.

Pelvic ultrasonography demonstrated an endometrial polyp, for which she underwent hysteroscopy and polypectomy. Fertility

Citation: Okwuegbuna T, Ade-Conde AJ. Gestational Choriocarcinoma Presenting Four Weeks After Term Delivery: A Case Report. Case Rep Rev. 2026;6(4):101.

investigations subsequently continued, and the patient conceived spontaneously. Early obstetric ultrasonography demonstrated a single intrauterine gestational sac. Routine prenatal laboratory investigations indicated that she was non-immune to rubella.

At 13 weeks' gestation, she experienced an episode of postcoital bleeding. Ultrasonography demonstrated a viable pregnancy without evidence of fetal compromise, and progesterone therapy was initiated. At 39 weeks' gestation, the patient developed pre-eclampsia without severe features and underwent induction of labour. She subsequently delivered a term infant by vacuum-assisted vaginal delivery.

Four weeks postpartum, the patient presented with heavy vaginal bleeding and passage of blood clots without associated abdominal or pelvic pain. Pelvic ultrasonography demonstrated a 2.8 × 1.6 × 2.1 cm hyperechoic vascular lesion within the endometrial cavity. Based on the clinical presentation and imaging findings, retained products of conception were initially suspected.

Laboratory investigations demonstrated a markedly elevated serum β-hCG concentration of 55,887 IU/L and a serum progesterone concentration of 5.88 nmol/L. The patient denied the possibility of another pregnancy, or twin pregnancy. Given the clinical, biochemical, and radiological findings, the patient underwent uterine evacuation.

Pathological Findings

Gross examination of the uterine evacuation specimen demonstrated multiple fragments of red-brown haemorrhagic tissue measuring 10 × 10 × 1 cm in aggregate. No fetal parts were identified.

Histological examination demonstrated a markedly atypical trophoblastic proliferation within a background of endometrial tissue, fibrin, and haemorrhage. The neoplastic proliferation comprised a triphasic population of cytotrophoblast, syncytiotrophoblast, and intermediate trophoblast. The tumour cells demonstrated marked cytological atypia with enlarged hyperchromatic nuclei and were arranged in cohesive clusters. No chorionic villi were identified.

Immunohistochemical studies demonstrated diffuse expression of pancytokeratin, β-hCG, and GATA3. Inhibin and SALL4 showed focal expression, while rare tumour cells were positive for p63. The Ki-67 proliferation index was high, estimated at approximately 60–70%. The tumour cells were negative for epithelial membrane antigen (EMA).

The overall morphological and immunohistochemical findings were consistent with gestational choriocarcinoma.

Clinical Course and Management

One week following uterine evacuation, the patient's serum β-hCG concentration decreased to approximately 9,000 IU/L. Two weeks following evacuation, it declined further to approximately 2,000 IU/L. However, one week later, the β-hCG concentration increased markedly to 34,750 IU/L, indicating persistent gestational trophoblastic neoplasia and the patient was referred to the regional cancer centre. Her β-HCG results trend is illustrated in Figure 1.

Repeat pelvic ultrasonography demonstrated intrauterine disease measuring approximately 4 cm in maximal dimension, with no adnexal masses identified. Following clinical staging and risk assessment, the disease was classified as International Federation of Gynecology and Obstetrics (FIGO) stage I gestational trophoblastic neoplasia, with a modified WHO prognostic risk score of 5.

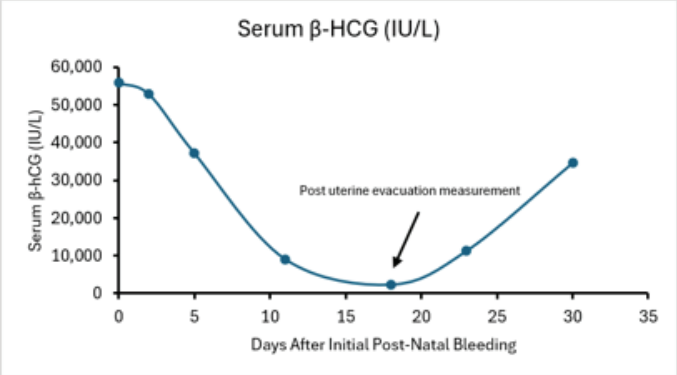

Figure 1: *Trend of β-hCG levels.*

Treatment options, including single-agent chemotherapy with dactinomycin and hysterectomy, were discussed with the patient. Following counselling, she elected surgical management and subsequently underwent hysterectomy at the cancer centre, where her ongoing oncologic care was continued. Further information regarding the hysterectomy pathology was not available for inclusion in this report.

Discussion and Conclusion

Gestational choriocarcinoma following a term pregnancy is uncommon and may present with nonspecific postpartum symptoms that overlap with more frequent obstetric complications such as postpartum vaginal bleeding [4,5]. The clinical presentation in this case illustrates this diagnostic challenge. The patient presented heavy vaginal bleeding four weeks after delivery, together with a vascular intrauterine lesion, which initially raised suspicion for retained products of conception. The markedly elevated serum β-hCG concentration prompted further investigation, while histopathological examination of the uterine evacuation specimen established the diagnosis of gestational choriocarcinoma. This emphasizes the value of quantitative β-hCG measurements in women with unexplained persistent or heavy postpartum bleeding.

This case emphasizes the importance of maintaining a high index of suspicion for gestational trophoblastic neoplasia in patients presenting with unexplained or persistent postpartum bleeding, even following an apparently uncomplicated term pregnancy. Quantitative serum β-hCG measurement provides a readily available, non-invasive tool for identifying and subsequently monitoring gestational trophoblastic neoplasia. Histopathological examination remains essential for establishing the specific diagnosis when tissue is available.

The initial decline followed by a marked rise in serum β-hCG in this patient further demonstrates the importance of serial β-hCG monitoring after diagnosis. The initial decline in β-hCG serum levels following uterine evacuation seemed to display a favourable response. However, the concentration subsequently increased to 34,750 IU/L showing that the initial decline did not indicate resolution of the disease. Rather, continued serial measurements revealed persistent gestation carcinoma. This observation highlights an important clinical principle: a single declining β-hCG value following uterine evacuation should not be interpreted as evidence of disease resolution in a patient with suspected or confirmed choriocarcinoma.

Following identification of persistent disease and clinical staging, the patient elected hysterectomy and transferred her ongoing care to another institution. During a telephone follow-up two years after the initial diagnosis, the patient reported that the post-treatment surveillance consisted of weekly quantitative β-hCG measurements for the first six months. She indicated that her most recent measurement was performed in April 2026. According to the patient, her latest oncology assessment demonstrated no evidence of residual or recurrent disease. She reported being in good health, with both herself and her child doing well.

Although the detailed operative pathology, chemotherapy, and surveillance results were unavailable, the patient reported clinical outcome was favourable. This case illustrates the importance of timely recognition and continued β-hCG monitoring to identify persistent disease despite an initially reassuring biochemical response.

References

1. Camilleri G, Calleja-Aguis J, Said E. Trophoblastic disease and choriocarcinoma. European Journal of Surgical Oncology. 2025;51(4):108727. doi:10.1016/j.ejso.2024.108727
2. Kaplan CG. Gestational Pathology. In: Modern Surgical Pathology. Elsevier; 2009:1409-1428. doi:10.1016/B978-1-4160-3966-2.00040-0
3. Baltazar JC. Epidemiological features of choriocarcinoma. Bull World Health Organ. 1976;54(5):523-532.
4. Katsanevakis E, Oatham A, Mathew D. Choriocarcinoma After Full-Term Pregnancy: A Case Report and Review of the Literature. Cureus. Published online February 14, 2022. doi:10.7759/cureus.22200
5. Dai GL, Tang FR, Ma Y, Wang DQ. Postpartum choriocarcinoma – a rare cause of delayed postpartum hemorrhage: Four case reports and literature review. Medicine. 2024;103(11):e37510. doi:10.1097/MD.0000000000037510